



Long-term efficacy of a high power diode laser for hair removal

Introduction

- Many patients complain of problems regarding excess hair growth such as hirsutism and hypertrichosis
- In the last few years the technology of laser assisted hair removal is advancing rapidly using ruby laser (694 nm), alexandrite laser (755 nm) or diode laser (810 nm)

Aim of the Study

- To investigate the longterm efficacy of a high power diode laser for hair removal:
 - Volunteers (study I) and patients using a spotsize of 8 mm
 - Volunteers (study II) using an enlarged spotsize of 12 mm

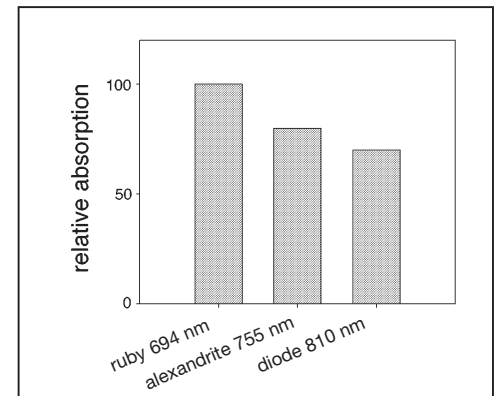


Figure 1: Absorption of melanin at three different wavelengths normalized to 694 nm (ruby laser)

Methods

- Laser therapy was performed using a high power diode laser (810 nm)
- The number of re-growing hair was counted four weeks and three months after the last laser treatment
- The ratio of hairs in the treated area to an untreated area nearby, which served as control, was referred to as re-growth
- Punch biopsies for histological evaluation of hair follicles were taken 24 h after laser treatment

Study I

- Pulse duration up to 50 ms, spotsize 8 mm
- Fluence up to 44 J/cm²
- Forty consenting volunteers were treated three times on the lower or upper legs at regular time intervals of two to three weeks
- Skin types I–III

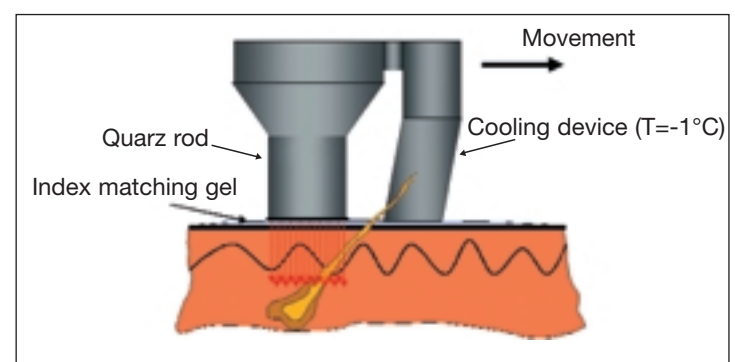
Other treatment sites

- Pulse duration up to 50 ms, spotsize 8 mm
- Fluence up to 44 J/cm²
- Patients were treated at different sites
- Regular treatment intervals of two to three weeks
- Skin types I–III

Study II

- Pulse duration up to 60 ms, spotsize 12 mm
- Fluence up to 40 J/cm²
- Twenty consenting volunteers were treated three times on the lower or upper legs at regular time intervals of two to three weeks
- Skin types I–III

- To avoid side-effects the skin was cooled directly before laser treatment using a cooling device



Results study I

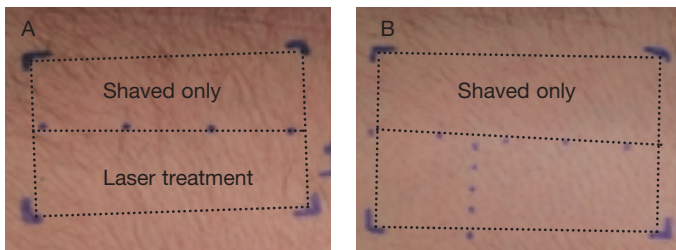


Figure 2: Upper leg of a volunteer before laser treatment (A) and 4 weeks (B) after the third treatment (8 mm spotsize, 44 J/cm²)

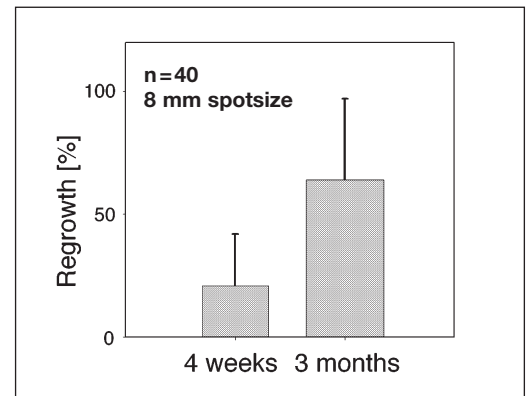


Figure 3: Efficacy of laser-assisted hair removal using the diode laser 4 weeks and 3 month after the third laser treatment

Results at other treatment sites

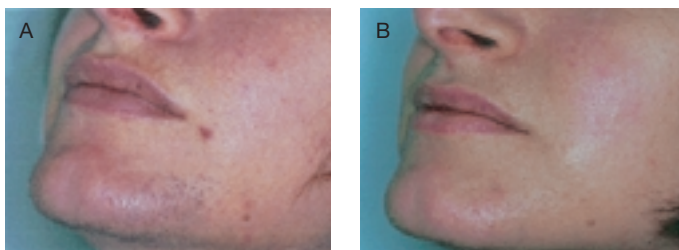


Figure 4: The chin of a female patient before laser treatment (A) and 8 weeks (B) after the third laser treatment (8mm spotsize, 36 J/cm²)

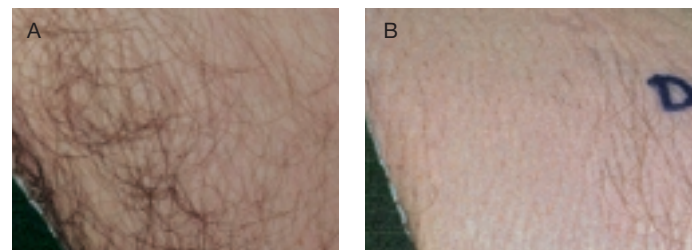


Figure 5: Bikini site of a female patient before laser treatment (A) and 8 weeks (B) after the third laser treatment (8mm spotsize, 36 J/cm²)

Results study II

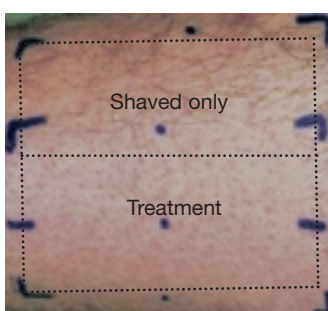


Figure 6: Upper leg of a volunteer 4 weeks after the third treatment (12 mm spotsize, 40 J/cm²)

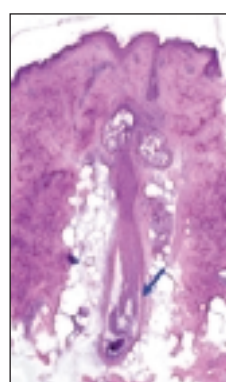


Figure 7: Histology showed that the structure of hairs was significantly altered. The hair shafts showed fragmentation. The follicular epithelium was ruptured (arrow), homogenized and the surrounding area showed a dense inflammatory infiltrate consisting of neutrophil granulocytes. The epidermis remained unaltered (HE-staining)

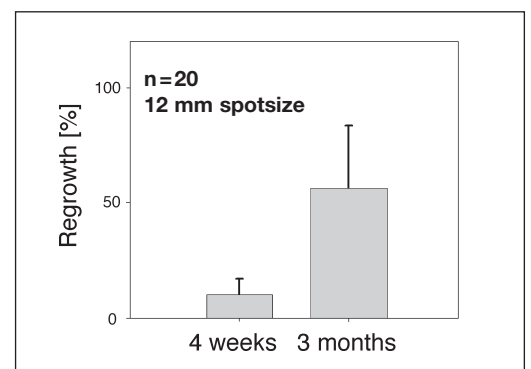


Figure 8: Efficacy of laser-assisted hair removal using the diode laser 4 weeks and 3 month after the third laser treatment

Conclusion

- The results provide evidence for an effective and long-lasting growth delay of hairs using a high power diode laser
- As immediate response to laser treatment perifollicular erythema and edema were seen but no severe side-effects such as scar formation or permanent pigmentary changes
- The use of 12 mm spotsize significantly improved the growth delay of hair measured 4 weeks after treatment
- Studies now should be performed to determine the treatment interval for maximal efficacy of laser assisted hair removal using a high power diode laser